


New Possibilities for Photo-thermal Laser Treatment of Macular Disease... Endpoint Management with PASCAL

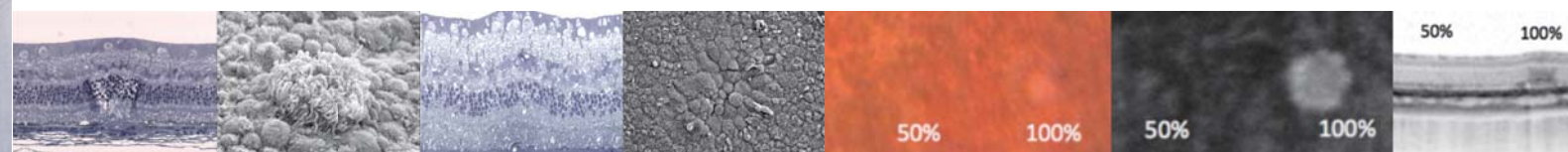
The 36th Annual Meeting of the Japanese Society of Ophthalmic Surgeons Luncheon Seminar 3



Chairman **Dr. Yuichiro Ogura**
(Nagoya City University)

Speaker 1 **Dr. Miho Nozaki**
(Nagoya City University)

Speaker 2 **Dr. Kishiko Ohkoshi**
(St. Luke's International Hospital)



* Not available in all countries, please check with your distributor for availability in your country.

IMPORTANT In order to obtain the best results with this instrument,
please be sure to review all user instructions prior to operation.

TOPCON CORPORATION
75-1 Hasunuma-cho, Itabashi-ku, Tokyo 174-8580, Japan. Phone:3-3558-2523/2522 Fax:3-3965-6898 www.topcon.co.jp

TOPCON MEDICAL SYSTEMS, INC.
111 Bauer Drive, Oakland, NJ 07436, U.S.A.
Phone:+1-201-599-5100 Fax:+1-201-599-5250 www.topconmedical.com

TOPCON CANADA INC.
110 Provencher Avenue, Boisbriand, QC J7G 1N1 CANADA
Phone:+1-450-430-7771 Fax:+1-450-430-6457 www.topcon.ca

TOPCON EUROPE MEDICAL B.V.
Essebaan 11; 2908 LJ Capelle a/d IJssel; THE NETHERLANDS
Phone:+31-(0)10-4585077 Fax:+31-(0)10-4585045
E-mail: medical@topcon.nl; www.topcon.eu

ITALY OFFICE
Viale dell'Industria 60; 20037 Paderno Dugnano; (Milano), ITALY
Phone:+39-02-9186671 Fax:+39-02-91081091 E-mail: topconitaly@tiscali.it; www.topcon.it

DANMARK OFFICE
Præstemarkavej 25; 4000 Roskilde, DANMARK
Phone:+45-46-327500 Fax:+45-46-327555
E-mail: topcon@topcondanmark.dk; www.topcondanmark.dk

IRELAND OFFICE
Unit 2/6, Blanchardstown, Corporate Park 2 Ballycoolin Dublin 15, IRELAND
Phone:+353-1-8975500 Fax:+353-1-2923915 E-mail: medical@topcon.ie; www.topcon.ie

TOPCON S.A.R.L.
BAT A1 3 route de la roquette 93206 SAINT DENIS CEDEX
Tel : +33 1 49 21 23 23 Fax : +33 1 49 21 23 24 E-mail: topcon@topcon.fr; www.topcon.fr

TOPCON DEUTSCHLAND G.m.b.H.
Hanns-Martin-Schleyer Strasse #1; D-47877 Willich, GERMANY
Phone:+49-(0)2154-8850 Fax:+49-(0)2154-885177 E-mail: medica@topcon.de; www.topcon.de

TOPCON SCANDINAVIA A.B.
Neogatan 2; P.O.Box 25; 43151 Mölndal, SWEDEN
Phone:+46-(0)31-7109200 Fax:+46-(0)31-7109249 E-mail: medical@topcon.se; www.topcon.se

TOPCON ESPAÑA S.A.

HEAD OFFICE
Frederic Mompou 4 Esc. A Bajos 3, 08960 Sant Just Desvern Barcelona, SPAIN
Phone:+34-93-4734057 Fax:+34-93-4733932 E-mail: medica@topcon.es; www.topcon.es

PORTUGAL OFFICE
Rua da Forte 6-6A L-0.22.2790-072 Camaxide, PORTUGAL
Phone:+351-210-994626 Fax:+351-210-938786 www.topcon.pt

TOPCON (GREAT BRITAIN) LTD.
Topcon House, Kennet Side, Bone Lane, Newbury, Berkshire RG14 5PX United Kingdom
Phone:+44-(0)1635-551120 Fax:+44-(0)1635-551170 E-mail: medical@topcon.co.uk; www.topcon.co.uk

TOPCON POLSKA Sp. z o.o.
ul. Walszawska 23; 42-470 Siewierz, POLAND
Phone:+48-(0)32-6705045 Fax:+48-(0)32-6713405 www.topcon-polska.pl

TOPCON SINGAPORE MEDICAL PTE. LTD.
60 Alexandra Terrace, #08-27 The Comtech, Singapore 118502
Phone:+65-68720606 Fax:+65-67736150 E-mail: medical_sales@topcon.com.sg; www.topcon.com.sg

TOPCON INSTRUMENTS (MALAYSIA) SDN.BHD.
No. D1, (Ground Floor), Jalan Excalta 2, Off Jalan Ampang Putra,
Taman Ampang Hilir, 55100 Kuala Lumpur, MALAYSIA
Phone:+60-(0)3-42709866 Fax:+60-(0)3-42709766

TOPCON INSTRUMENTS (THAILAND) CO.,LTD.
77/162 Sinnsathorn Tower, 37th Floor, Krungthornburi Rd., Klongtonnai,
Klongsarn, Bangkok 10500, THAILAND
Phone:+66-(0)2-440-1152-7 Fax:+66-(0)2-440-1158

TOPCON CORPORATION BEIJING OFFICE
Block No.9, Kangding Street Beijing Economic-Technological Development Area,
Beijing, 100176, CHINA
Phone:+86-(0)10-6780-2799 Fax:+86-(0)10-6780-2790

TOPCON CORPORATION SHANGHAI OFFICE
14L Huamin Empire Plaza, No.726, Yan-an Xi Road,
Shanghai, 200050, CHINA
Phone:+86-(0)21-5238-7722 Fax:+86-(0)21-5237-0761

TOPCON CORPORATION BEIRUT OFFICE
P.O.Box 70-1002 Antelias, Beirut, LEBANON
Phone:+961-4-523525/523526 Fax:+961-4-521119

TOPCON CORPORATION DUBAI OFFICE
P.O.Box 293705, Dubai Airport Free Zone L.L.U. J-12, Dubai, U.A.E
Phone:+971-4-299-5900 Fax:+971-4-299-5901



New Possibilities for Photo-thermal Laser Treatment of Macular Disease... Endpoint Management with PASCAL



Chairman: Dr. Yuichiro Ogura (Nagoya City University)

Chairman's words

Although there have been reports that subthreshold diode micropulse laser photocoagulation is effective for diabetic macular edema, it is currently not widely used even though it is effective because traditional subthreshold photocoagulation requires a specialized photocoagulation device. With this new Endpoint Management software, subthreshold photocoagulation is now possible using PASCAL and we will be hearing about it from two doctors.



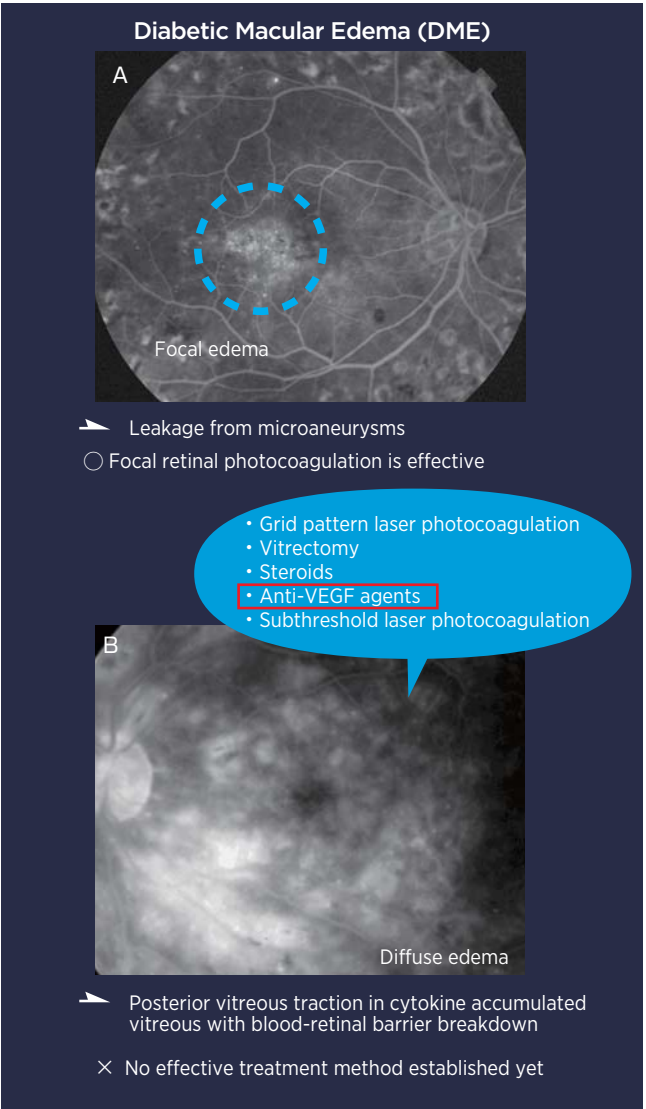
Speaker 1: Dr. Miho Nozaki (Nagoya City University)

Clinical Experience Using PASCAL Endpoint Management

Introduction

Diabetic Retinopathy is one of the leading causes of blindness in people of working age. Diabetic macular edema (DME) is one of the most common problems associated with Diabetic Retinopathy. DME can be categorized into two main types: focal edema and diffuse edema (Fig. 1). Focal edema is mainly caused by leakage from microaneurysms and focal (direct) photocoagulation (i.e. Fig. 1A_light blue circle) is considered effective, whereas diffuse edema combines various factors and there is no effective treatment method established (Fig.1B). Grid pattern laser photocoagulation, vitrectomy, steroids, anti-VEGF agents, and subthreshold laser photocoagulation have been used as treatment for diffuse edema. Of these treatments, recent clinical study results have reported that anti-VEGF agents are effective for diffuse DME and there are concerns that the future generation will only use intravitreal injection. The most recent clinical study results announced by DRCR.net. These are the results over 3 years of observation comparing the efficacy of Ranibizumab alone or in combination with laser treatment for DME. Even based on these results, you can see that this study

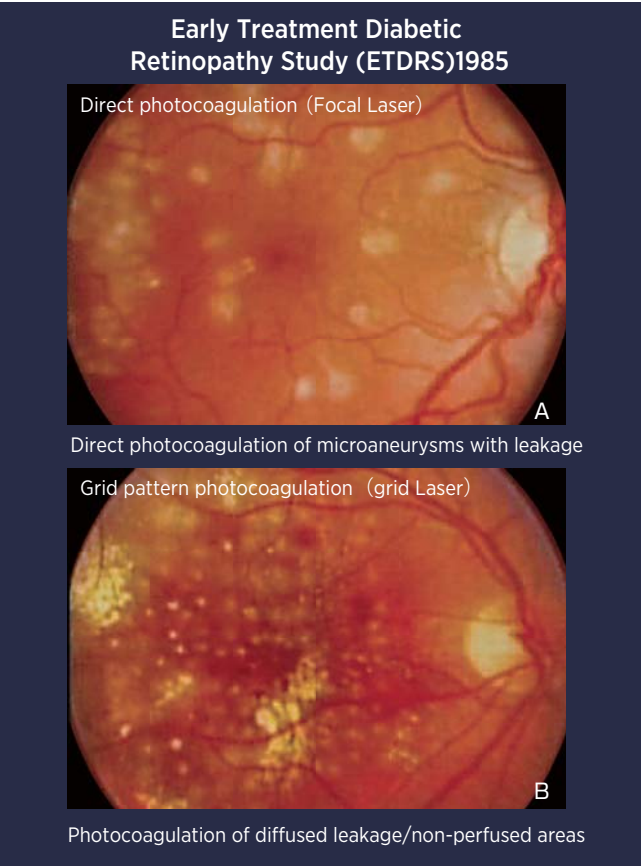
found very good results can be obtained for both visual acuity and retinal thickness using Ranibizumab injections alone, which creates an impression that anti-VEGF agents could become the exclusive treatment for DME. On the other hand, there is data available on how much anti-VEGF agents were actually used in the USA, and, while the DRCR.net protocol requires using 9 or more injections annually for DME, the average annual injections in America is actually only 2.9 injections. In addition, unlike the actual clinical study protocol, it is only used 2.8 injections for BRVO and 3.1 injections for CRVO which is completely different from the clinical study protocol. The most likely reason is that monthly injection of anti-VEGF agents as recommended by clinical studies is very cumbersome and practically impossible. This means that other tools are necessary since relying solely on anti-VEGF agents is difficult and not practical for DME. DME patients tend to be younger, more active, and have busier schedules than AMD patients so monthly office visits are not possible. We need another solution. Given these circumstances, I want to introduce subthreshold photocoagulation, which previously could only be conducted using a specialized laser, is now possible using PASCAL laser with Endpoint Management software.



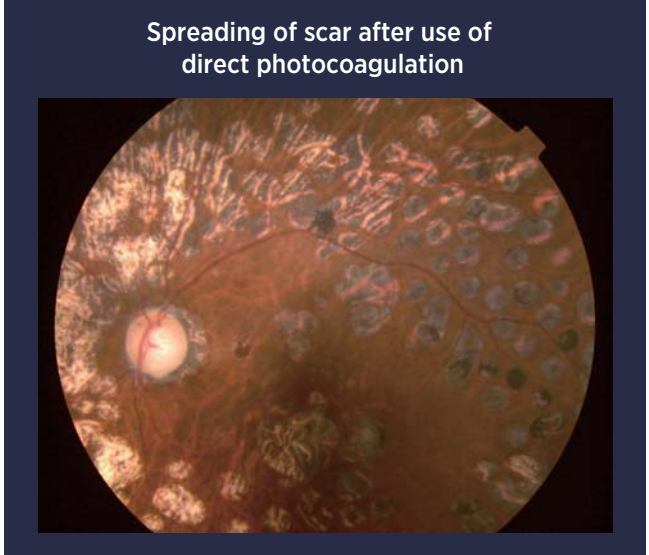
(Figure 1)

Background of the Development for Endpoint Management

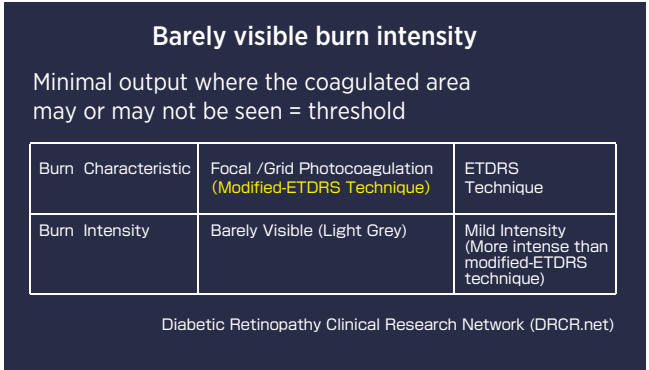
In the 1980s, the ETDRS study established a definition for edema called Clinically Significant Macula Edema (CSME), and reported that direct photocoagulation of microaneurysms for focal edema or grid pattern photocoagulation as demonstrated in Fig. 2B for diffused leakage helps prevent from visual acuity loss. However, problems occurred when scars from photocoagulation expand and fused together and extended into the central fovea causing a decrease in visual acuity (Fig. 3), or when scars due to grid pattern photocoagulation fused together and spread after a couple of years and lead to large circular atrophic areas and thereby annular scotomas. As such, laser photocoagulation was avoided for a time and numerous reports on efficacy of vitrectomy for DME were reported in the 90s in Japan. Since then, rather than the photocoagulation method proposed by ETDRS which recommended heavy burns, the Modified ETDRS technique was recommended which utilized lighter less damaging burn spots with wider spacing. This method aims for using Barely Visible burn spots, which may or may not be seen, which was shown to be equally clinically effective and is used for DRCR.net clinical studies (Fig. 4).



(Figure 2)



(Figure 3)




(Figure 4)

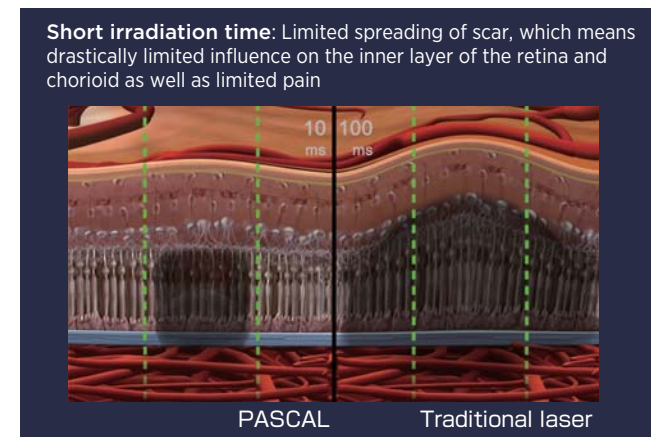
One of the breakthroughs for ophthalmologic laser treatment is PASCAL's Pattern Scanning Laser which can apply many burn spots at once. There are many positive characteristics of the PASCAL laser.

First, with PASCAL you can choose various patterns that allow you to apply many burn spots in rapid succession. Available patterns include square grids of various sizes, wedges, circles, and more. In addition, contrary to traditional photocoagulation methods, the spot burn time is 20ms, which is very short and 1/10 of the traditional laser. Applied over a large treatment area, this reduction in total treatment time is very significant. Also, because it can coagulate using various patterns, it has the characteristic of being able to automatically control the burn spot spacing which was not possible before. Photocoagulated areas with PASCAL feature very uniform burn spots compared to traditional lasers. Traditional laser have a slight spike as the laser discharges and later settles down to the desired output value; however, for PASCAL, the laser constantly is discharging and the galvanometer mirror adjusts the laser ON/OFF to the retina and is designed so a constant power output is achieved (Fig. 5). The advantage of a short burn time is that the scar does not spread laterally which means there is less retinal atrophy and consequentially less vision loss compared to traditional laser treatment. In addition, a short burn time has drastically limited damage on the inner layer of the retina and choroid. This allows limited thermodiffusion to the choroid and has the advantage of limiting the amount of pain to the patient (Fig. 6). In Figure 7, you can see the effects of laser burns of various intensities and various durations. The fundus images are on the left and the OCT images are on the right. At the top the burn was moderate at 100 ms, on the right you can see the 400 spot size used for the burn grew to 530 microns after the application. A moderate burn at 20 ms resulted in a burn spot size of 482 microns. Both of these moderate burn spots grew in size after the application and they will continue to grow over time. The burn spot size did not increase for a light burn with 20 ms, and the burn spot size for a barely visible burn at 20 ms actually shrank in size. Because the burn spot size actually decreases over time with light and barely visible burns, the number of spots applied needs to be increased to keep the treatment area covered equal. Fig. 8 is a chart showing the calculations based on the lateral size of the OCT image shown in Fig. 7. For example when applying 1000 spots with 100ms duration, in order to treat the same area using a 20ms duration burn, it is calculated that 1464 spots will be needed in order to cover the same treatment area. Additionally, if the intensity of the burn is further reduced, it is necessary to use about 2000 spots which is double the original value. Therefore, compared to the traditional photocoagulation method, it is necessary to apply more burn spots when using PASCAL with short spot duration and light burns. In addition to being able to apply many consistent burns in a convenient and rapid manner, the advantage of PASCAL is you can limit the spread of scarring by using a short burn time and minimize damage to the inner layer.

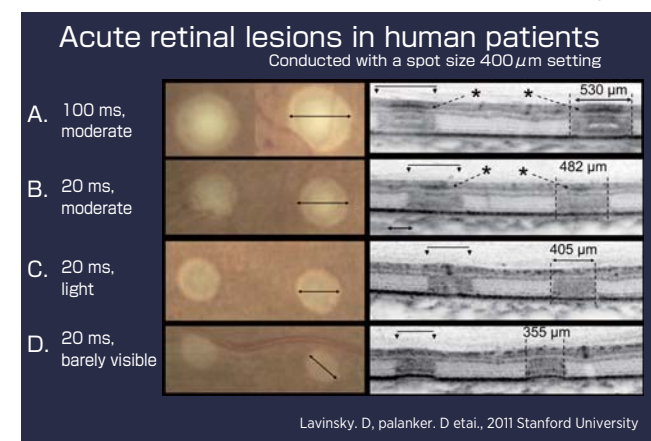
The idea for Endpoint Management was to apply these advantages of PASCAL and to further selectively target retinal pigment epithelial cells (RPE) only through the application of subthreshold photocoagulation in a consistent and reproducible manner.



(Figure 5)



(Figure 6)



(Figure 7)

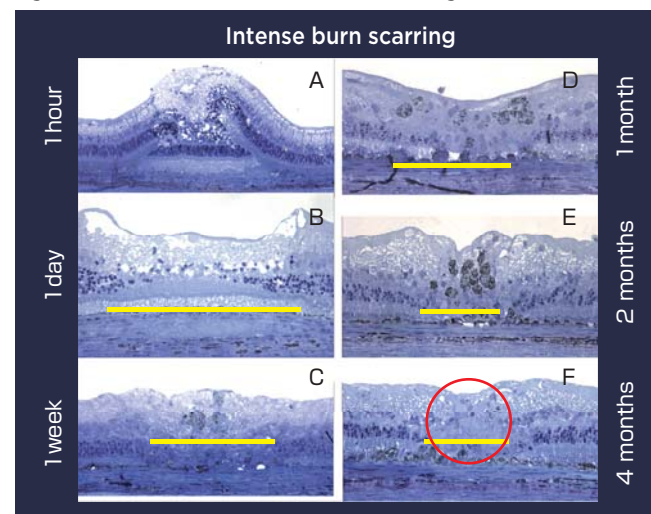
Adjusting the Number of Spots			
Pulse duration	100ms	20ms	20ms
Lesion grade	Moderate	Moderate	Light
Number of Lesions	1000	1464	1979
Percent Increase		40%	100%

(Figure 8)

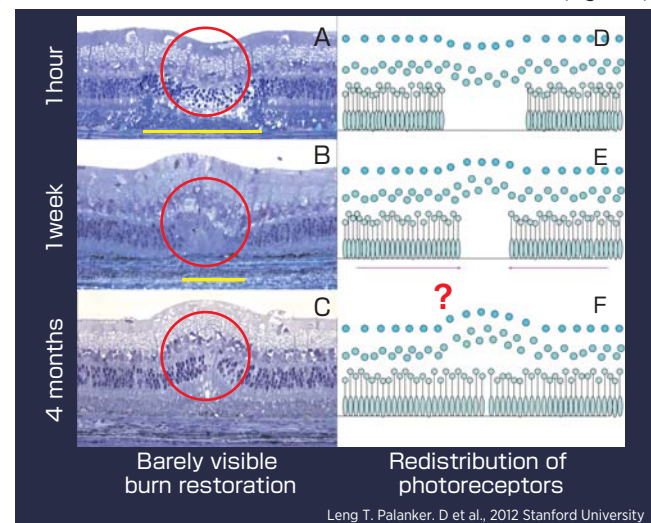
What is Endpoint Management?

Endpoint management is a method to precisely control and optimize the laser power and duration in order to achieve subthreshold laser treatment to the eye in order to eliminate negative consequences (scarring, vision loss) while at the same time maintaining clinical efficacy. Fig. 9 is a histological image of the tissue change after conducting laser photocoagulation using a traditional intense burn. All the cells of the inner layer are destroyed as if they were blown away after 1 hour; however, you can see that this damage gets gradually repaired after 1 day (Fig. 9B). However, repair of the photoreceptor layer within the scar did not occur even after 4 months (Fig. 9F_Red circle). Figure 10 shows the histology after the application of a barely visible burn over time. It can be seen that the healing response is more complete and the photoreceptors actually fill in the original burn location by 4 months time. (Fig. 10B, C).

Fig. 11 shows the tissue effects of various burn spot intensities and durations. The fundus image is on the left and OCT images are on the right for both acute effects and after 12 months. A healing response can be seen in the OCT images for all burns, however the healing is more complete with lighter burns at shorter durations. For blight burns at 20 ms

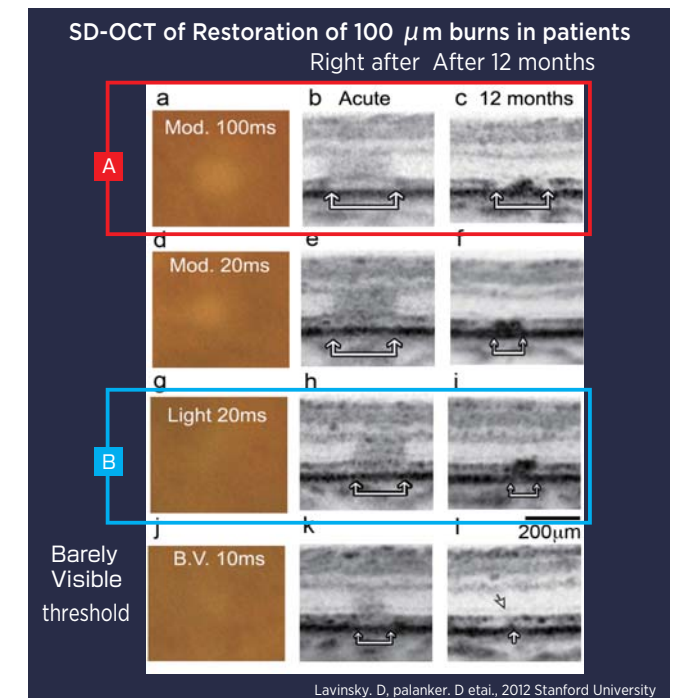


(Figure 9)

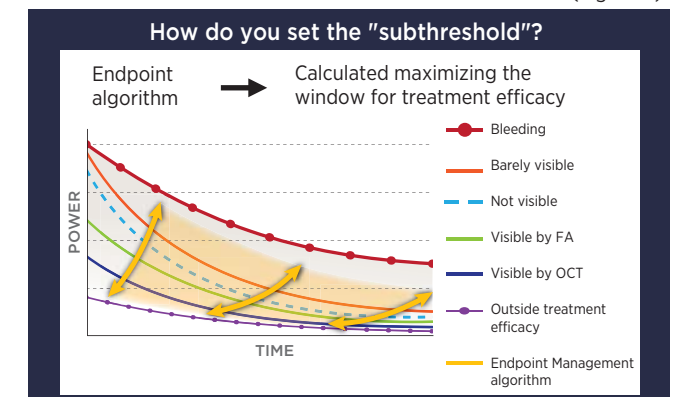


(Figure 10)

pulse duration the healing is nearly complete after 12 months and for barely visible burns the retina appears nearly normal (non-damaged) after 12 months. Notice the IS/OS boundary of photoreceptor cells is intact for light burns at short durations. When conducting laser photocoagulation with Endpoint Management, the most important factor is how to set the "subthreshold" level which has treatment efficacy after setting the Barely Visible value (threshold). With Endpoint Management, the user chooses what level of subthreshold treatment to provide. The user chooses the percentage of energy applied to the burn spot relative to the original barely visible level. In other words, the user first sets a barely visible burn level. This becomes the 100% level for Endpoint Management. Then the user chooses some percentage below that level, for example 75% or 50% or less (any percent level can be chosen). The Endpoint Management software then automatically adjusts the power and duration using a sophisticated algorithm to achieve the desired energy output. The algorithm is called the Arrhenius Integral and it basically optimizes the power and duration in order to maximize the therapeutic treatment window (see Figure 12). This provides better clinical outcomes and more control than other subthreshold techniques such as the micropulse method.



(Figure 11)



(Figure 12)



The effect of using various levels of Endpoint Management for laser burn applications can be seen in Figure 13. This figure shows the laser-tissue interaction at various levels of Endpoint Management. The figure shows tissue effects using various imaging methodologies including fundus photographs (top row), Fluorescein Angiography (FA-middle row), and OCT (bottom row). To the right of this figure is a magnified view of all three imaging methods for various intensity levels. Figure 13A shows the result at the barely visible level or Endpoint Management at 100%, Figure 13B are the results with Endpoint Management at 50%, and Figure 13C are the results with Endpoint Management at 30%. The burn effects are visible on all three imaging types at 100% (Fig.13A). However at 50% the burn is not visible with fundus photography and only faintly visible on FA or OCT. However at 30% there is no detectable damage with any imaging device. Endpoint Management at 30% or lower can be considered non-damaging or more precisely it is photo-thermal stimulation of the RPE. It is interesting to note that anecdotal reports show clinical efficacy even at this low, non-damaging level. Endpoint Management at slightly higher levels, greater than 30% but lower than 100% result in subthreshold damage meaning that the burn effects on the tissue cannot be seen clinically or with fundus photography, but they are visible on FA and/or OCT (see Figure 13 at 75% level). The most clinically effective level to use is not known at this time and it may depend on the stage of pathology and the preference of the clinician. However at non-damaging levels of 30% or less, treatment close to the fovea is safe and effective.

The laser effects on tissue with Endpoint Management are further elucidated in Figures 14 and 15. These figures show the effects of Endpoint Management with fundus photography, FA, OCT, and histology and scanning electron microscopy (SEM) at the barely visible level (Figure 14) and

the 50% level (Figure 15). It can be seen that the histology reveals initial damage at the barely visible level at 1 hour, but there is a large healing response after 2 months. SEM results in Figure 14 show RPE damage at 1 hour, but complete RPE healing at 2 months. In Figure 16, the histology shows minor damage at one hour, and healing at 3 days, but the SEM shows damage to only a few RPE cells at one hour, and complete healing of the RPE layer at 3 days. Taken together, these laser-tissue interactions with Endpoint Management suggest controlled and minimal damage with endpoint management where predictable tissue effects can be achieved by choosing various levels of Endpoint Management. Barely visible burns result in visible damage that heals over time, while subvisible burns (Endpoint Management levels below 100%) result in non-visible damage but controlled effects on the RPE and photoreceptors with healing over time.

Experience Using Endpoint Management

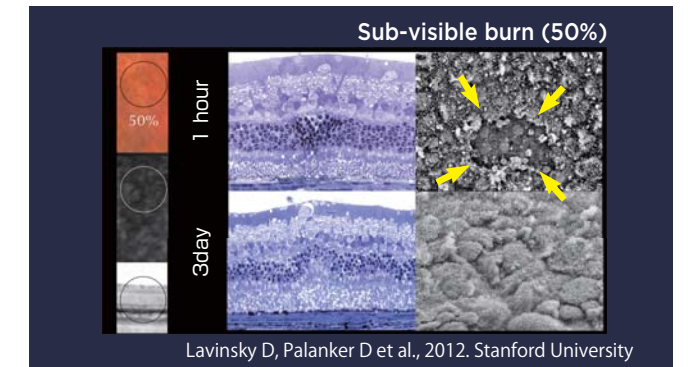
Another major characteristic of Endpoint Management is the landmark setting. If a 50% or 30% setting is used, spots burned with Endpoint Management cannot be visually confirmed using a color fundus photograph and the clinician cannot tell which areas were burned. If you turn the landmark setting ON with Endpoint Management, the spots in the four corners of the pattern are set to the 100% level (barely visible level) so you can visually tell which parts were treated (Fig. 16). In this way, the areas of treatment are marked and can be clinically seen, but the location of the subthreshold spots are known (inside the Landmarks).

Case demonstration


Figure 17 shows the results from a 61 year old female with an intraocular lens inserted in both eyes and severe non-proliferative diabetic retinopathy (NPDR). Endpoint Management was performed using a 50% setting for areas with fluorescence leakage prior to conducting panretinal laser photocoagulation. Figure 18 shows the FA results before treatment and after laser treatment with Endpoint Management. The reduction in leakage is clearly visible demonstrating the clinical efficacy of Endpoint Management for DME. Also notice in addition to the reduced leakage, the burn spots are not visible.

Summary

Endpoint Management can selectively target RPE alone and can be used to precisely control the desired tissue effects. Higher levels of Endpoint Management will affect the RPE and some outer retinal layers which will heal over time, while lower levels of Endpoint Management will selectively target the RPE layer sparing the retina completely. Endpoint Management allows sub-threshold or non-damaging treatment while maintaining clinical efficacy. This has the advantage of reducing or eliminating inner retinal damage and selectively affecting the RPE generating a beneficial healing response. It potentially offers the ability for retreatment as well. Due to PASCAL's Endpoint Management, we have entered an era where it is possible to conduct Photo-stimulation Laser Treatment that was not possible until now. Early clinical cases suggest Endpoint management is safe and clinically effective. Future work will determine which percent levels of treatment are most effective for what type of patients.

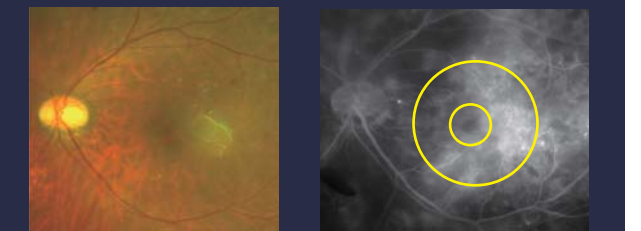


(Figure 15)



(Figure 16)

61 year old, female Severe NPDR in both eyes, intraocular implant inserted

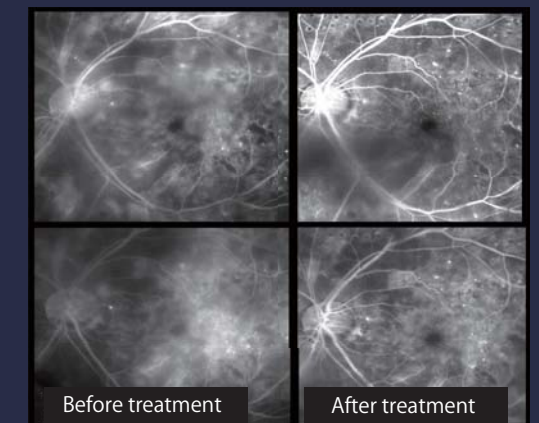


Conducting Endpoint Management

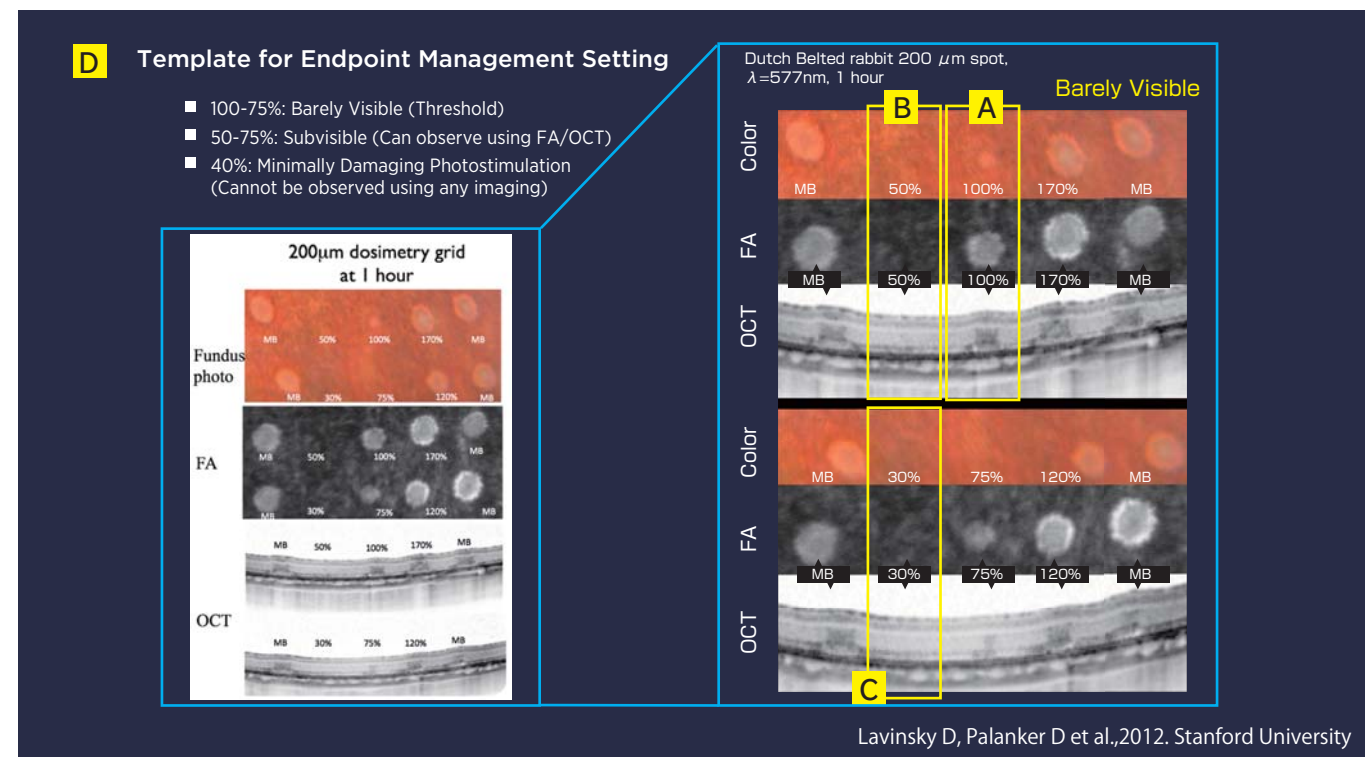
Output 175mW/50% Irradiation time 15msec
Size 200 μ m spacing 0.5

(Figure 17)

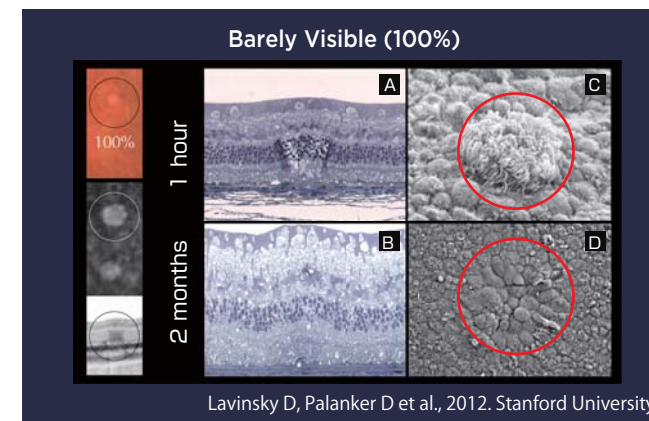
6 weeks after conducting Endpoint Management



(Figure 18)



(Figure 13)



(Figure 14)



Speaker 2: Dr. Kishiko Ohkoshi
(St. Luke's International Hospital)

Future Direction of Non-invasive Laser Treatment Strategy

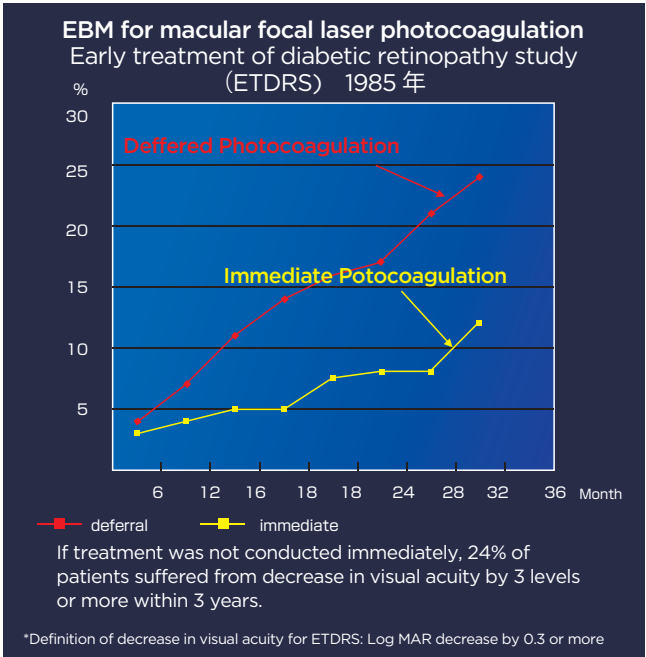
Introduction

For approximately 20 years, research has been conducted on how to make laser treatment for macular edema as minimally invasive as possible. I would like to introduce software recently developed by Topcon called Endpoint Management which makes minimally invasive treatment possible. If diabetic macular edema is left untreated, it causes a drastic decrease in visual acuity. In 1985, a multicenter comparative clinical trial in United States (ETDRS) was conducted to compare a group of patients who underwent macular laser photocoagulation for their diabetic macular edema immediately and a group of patients who underwent deferred laser. As a result, it was shown that a decrease in visual acuity was reduced by approximately half in those who underwent the immediate laser procedure (Fig. 1). The important thing here is that approximately 1 in 4 patients who did not undergo immediate laser photocoagulation suffered from about a 15 word decrease in visual acuity. For example, this suggests that approximately 1 in 4 patients with a visual acuity of 1.0 eventually had a visual acuity of 0.5 or less, and demonstrates that leaving macular edema untreated is very dangerous. ETDRS recommended early diagnosis of diabetic macular edema and treating it with direct laser photocoagulation, grid pattern laser photocoagulation, or both. This method is also called Focal Photocoagulation, but, in order to differentiate it from other various photocoagulation methods developed later, it is referred to as ETDRS photocoagulation as well (Fig. 2). In the 1990s, complications associated to laser photocoagulation were reported. At the time, very intense laser burns were used and atrophic 'creep' occurred where burn scars enlarged over time and even encroached into the fovea resulting in peripheral and even central vision loss (Fig. 3). These complications created a definite scotoma within the visual field even though visual acuity improved, and it was clear that visual function would decrease. Although grid pattern laser photocoagulation is an effective treatment method, intense burns over a large area causes macular atrophy since it targets a fairly wide range (Fig. 4). Because of this complication, treatment slowly shifted to intravitreal pharmacotherapy or vitrectomy. Despite this trend away from lasers, some researchers have been working on the clinical efficacy of more minimally invasive laser procedures. Although grid pattern laser treatment is a treatment with high efficacy, it is unnecessary to use power that makes the burn spots completely white, and it was reported that edema sufficiently subsides even when the laser burn spots were very light and in some cases not even visible clinically. In order to avoid complications, in the 1990s, I thought of a way to widen the spacing between the coagulated areas themselves rather than just suppress output power and exposure

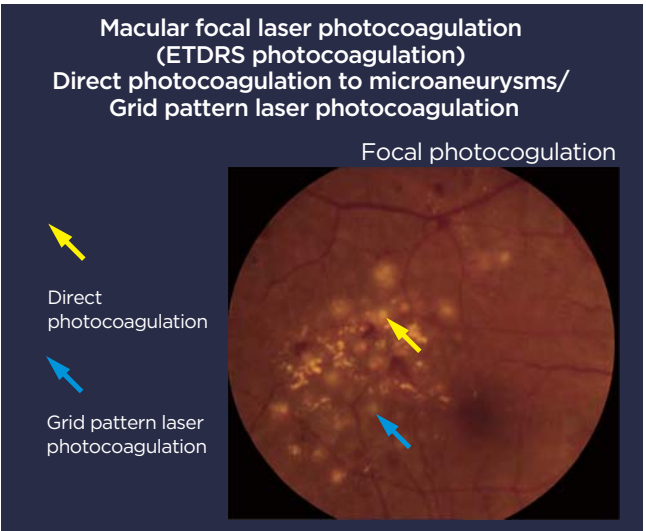
time. At the time, most of surgeons believed that it was safe to conduct laser photocoagulation using a weak output power and long exposure time, and there was a perception that it was dangerous to conduct laser photocoagulation under a short exposure time period. However, contrary to common practice, I set the coagulation time to less than 0.1 seconds and set the output power to minimal output where laser flecks will appear, which we called "highly scattered minimal burn grid pattern laser photocoagulation. Basically, I conducted threshold photocoagulation" (Fig. 5). Fig. 6 is a case from 20 years ago in which I conducted threshold photocoagulation. The color fundus photograph and OCT image was taken 8 years ago, but you can see that invasion was minimal and the IS/OS line was almost healed. However, "highly scattered minimal burn grid pattern laser photocoagulation" still leaves scars even though it is minimally invasive. In contrast, subthreshold diode laser micropulse photocoagulation is a laser photocoagulation that does not leave any scars. In addition, the meaning between micropulse and subthreshold coagulation is different so I will explain the two terms.

What is Micropulse?

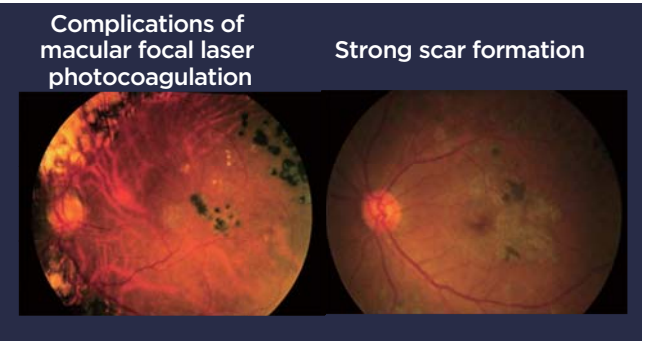
As the coagulation time of the laser is shortened, the temperature increases locally for RPE, and it does not disperse to affect other retinal layers. In other words, it is possible to set conditions so that other neural retina areas are not damaged. Contrary to traditional continuous wave lasers, subthreshold diode laser micropulse photocoagulation methodology utilizes short pulse durations to selectively affect the RPE layer. However a limitation is that the subthreshold treatment level cannot be precisely controlled or adjusted and in some cases the laser energy may be below the necessary therapeutic window needed for positive clinical outcomes (Fig. 7).



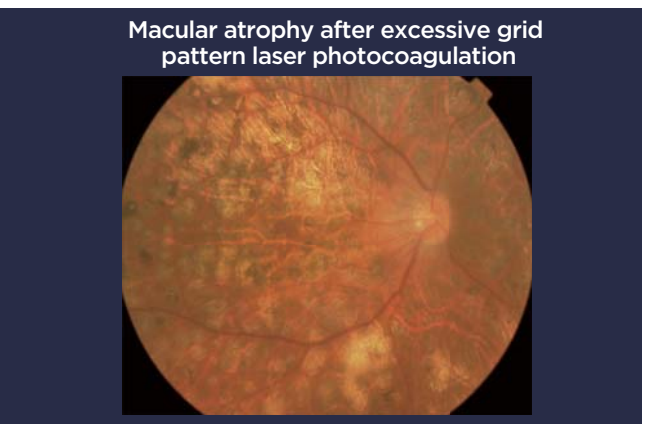
(Figure 1)



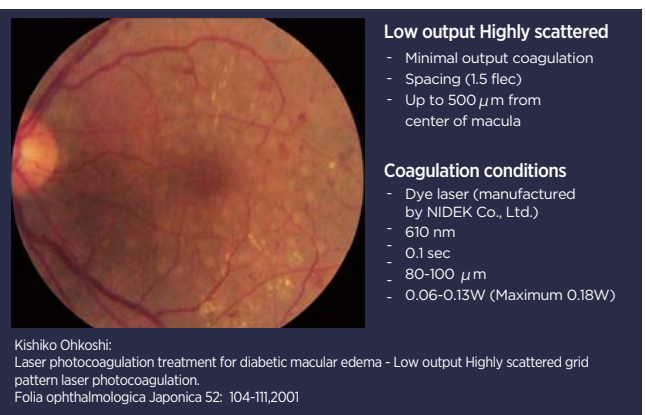
(Figure 2)



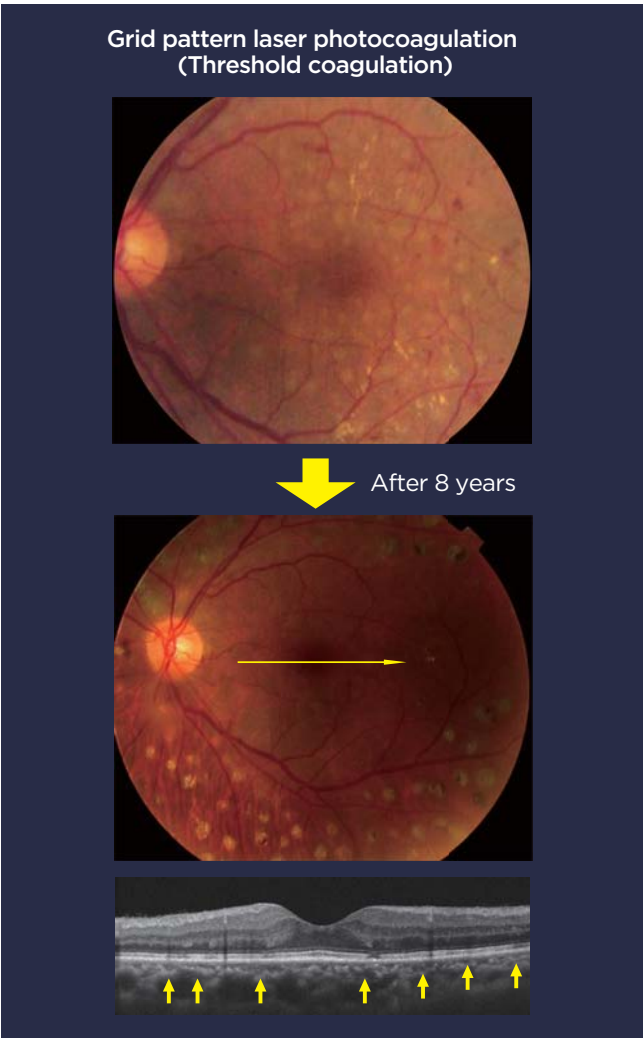(Figure 3)



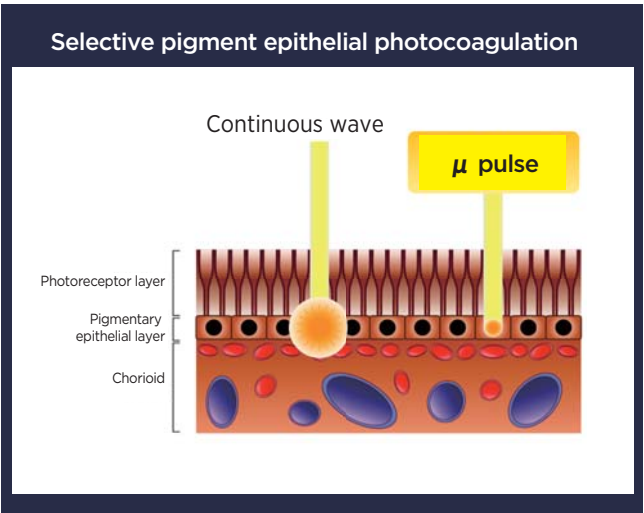
(Figure 4)



(Figure 5)



(Figure 6)



(Figure 7)

What is Subthreshold Photocoagulation?

Photocoagulation is a technique that can be conducted with or without use of micropulse and can have above threshold photocoagulation, threshold photocoagulation, and subthreshold photocoagulation (Fig. 8). Of these, subthreshold photocoagulation is a method where the burn spots cannot be seen with biomicroscopy. With micropulse and subthreshold photocoagulation, the treated areas cannot be seen on color fundus photograph, but they also cannot be seen on OCT or FA when the subthreshold level is adequately set. Subthreshold photocoagulation can be considered to be truly minimally invasive or non-damaging photocoagulation. A term sometimes used is photo-thermal stimulation since the RPE layer is heated and stimulated, but not destroyed.

Case: Diabetic Macular Edema (60 years old, male)

This is a patient who has diabetic macular edema and in whom triamcinolone and bevacizumab were ineffective and subthreshold diode laser micropulse photocoagulation was conducted. The edema clearly disappears within 5 months (Fig. 9). There are many papers already showing the efficacy of subthreshold diode laser micropulse photocoagulation, and it is a treatment method that has good efficacy. There are recent papers that claim that micropulse has superior efficacy in terms of improvement in visual acuity and decrease in central fovea retinal thickness compared to traditional ETDRS laser photocoagulation. However, setting the coagulation conditions for subthreshold coagulation is difficult and the challenge remained as to what % would provide sufficient efficacy and how to confirm this. In addition, the coagulation conditions differed depending on the surgeon and it is not possible to determine which coagulation condition is optimal. Furthermore, because the coagulated areas cannot be seen while treating with the laser, it was doubtful whether the intensity was enough to gain clinical efficacy, and the only way we knew it was effective was when we saw the edema subside in OCT images after a while (Fig. 10). It was necessary to calculate the energy used in subthreshold coagulation by yourself, and a switch to micropulse mode after setting the threshold and then perform the treatment, which made operability complicated (Fig. 11). Topcon began sales of PASCAL in April 2008 in Japan. The characteristics of PASCAL are: 1. High power, short duration make fast burn time using patterns for convenience and reducing total treatment time 2. lowering of total energy, and 3. a laser that was minimally invasive and had outer layer selective photocoagulation. The figure on the left is an image of the coagulated area using PASCAL for 0.02 seconds while the figure on the right is an image of the coagulated area using normal coagulation conditions for 0.2 seconds (Fig. 12). Although there are no differences on the OCT image right after treatment, there is localized change to the RPE and IS/OS in the one treated for 0.02 seconds. When you look at

the image 2 months after surgery you can see that there is almost no damage to the inner retinal layer. In contrast, there was damage to the inner layer for the condition that was treated for 0.2 seconds under normal coagulation conditions (Fig. 13). Another advantage of the minimally invasive PASCAL is that it is possible to conduct pattern grid treatment. Until now, surgeons had to treat each individual spot, but, since PASCAL can treat using a pattern, it allows for a steady laser photocoagulation that is not susceptible to the surgeon's skill. There is no significant difference since the number of data included is limited, but you can clearly see that the edema has subsided.

What is subthreshold photocoagulation?

Above threshold coagulation
Photocoagulation where coagulated areas are clear

Threshold coagulation
Start at minimal output and gradually increase it and irradiate it using a threshold level output which create barely visible burn.

Subthreshold photocoagulation
(Photocoagulation where coagulated areas cannot be seen)
Photocoagulation where coagulated area are invisible. Irradiate using an output that does not cause ophthalmoscopically visible burn by calculating the energy using the threshold output.

(Figure 8)

Case: 60 year old male with diabetic macular edema Triamcinolone and bevacizumab ineffective

IRIDEX Corporation IQ577

Coagulation conditions
Threshold setting:
CW
200 μ m
0.1 sec
0.12W
Irradiation:
Threshold 200% output
15% duty cycle
0.2 sec (0.24W)

(Figure 9)

Cannot confirm which portion was treated since coagulated areas cannot be seen.

Test treatment conducted using continuous wave outside the macula. 0.1 sec Threshold treatment

Double the output of test irradiation and change the time to 0.2 seconds. Coagulate at 15% duty cycle

● Test irradiation: Threshold coagulation ● Micropulse: Subthreshold coagulation

(Figure 10)

Operation is complicated since you have to calculate the energy for subthreshold photocoagulation by yourself.

Continuous wave 0.1 sec 200 μ m

Threshold setting

Switch to micropulse mode

Irradiation

0.1 sec

15% duty cycle

0.2 sec

Threshold 100mW~

Threshold *200% 200~250mW~

(Figure 11)

OCT image of 0.02 sec PASCAL and 0.2sec ablation

A. 0.02 seconds, PASCAL

B. 0.2 seconds, standard condition

Masafumi Hamada, et. al: The 66th Annual Congress of Japan Clinical Ophthalmology (2012, Kyoto City)

(Figure 12)

1 hour after surgery

0.02 sec, PASCAL

0.2 sec, standard condition

2 hours after surgery

0.02 sec, PASCAL

0.2 sec, standard condition

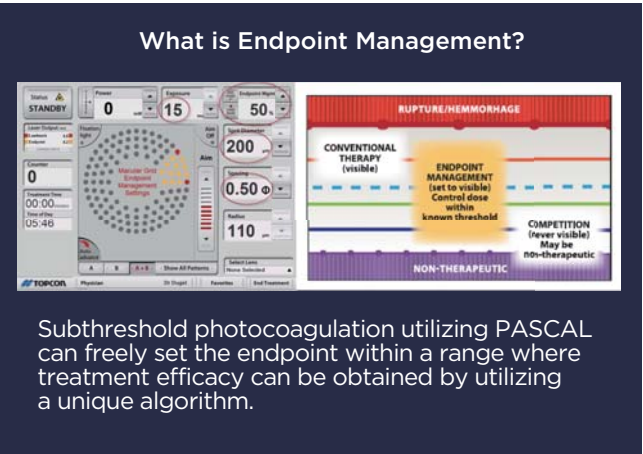
Masafumi Hamada, et. al: The 66th Annual Congress of Japan Clinical Ophthalmology (2012, Kyoto City)

(Figure 13)

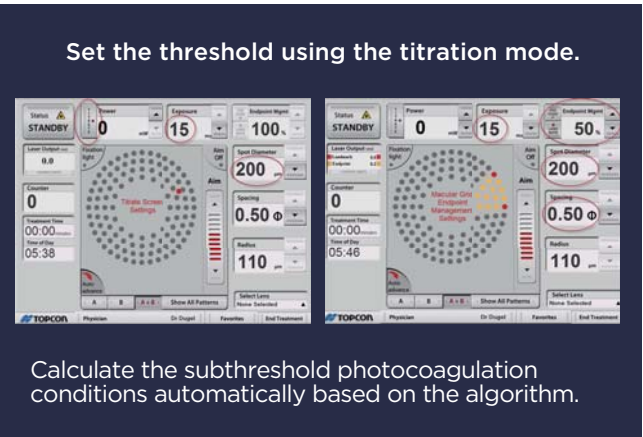
The characteristics of PASCAL grid are that it is minimally invasive, that a consistent, highly reproducible irradiation is possible regardless of the surgeon's skill, and that it can derive the point of fixation and safely irradiate. Since it is already possible to conduct a threshold level grid pattern laser photocoagulation using PASCAL's grid, I have always thought it would be nice if subthreshold photocoagulation could be conducted by PASCAL as well. Topcon developed software called Endpoint Management under such circumstances. Laser becomes a destructive treatment the more you raise energy. Adversely, if the energy is too little, it enters a non-therapeutic treatment range. However, PASCAL's Endpoint Management utilizes a unique algorithm that calculates the range in which therapeutic efficacy can be achieved and allows surgeons to freely set the Endpoint and conduct the desired irradiation (Fig. 14).

Procedure for Endpoint Management


The threshold level output power is set to obtain barely visible burn at approximately 200mW to 250mW using the titration mode, and irradiation is conducted after switching over to Endpoint Management. If you set the coagulation conditions to 50% at this time, the other parameters are automatically calculated by the device and changed to the optimal value (Fig. 15). In VIVO experiments, the level of tissue damage is altered by changing the parameter of the laser, which may cause different clinical results. For example, for a 0.01 second laser, you can see that the IS/OS line is almost fully repaired even when observing with an OCT. You can see that the photoreceptors are repaired after 4 months (Fig. 16). Therefore, even though it was thought that permanent tissue damage must be left in order for laser treatment to be effective, it is now becoming apparent that it is effective even when irradiating under conditions where repair can be made such as this. The level of tissue damage was not much of a concern with the traditional destructive laser; however, you can evaluate the level of tissue damage using methods such as fundus photograph, fluorescein angiography, OCT, and RPE Variability (Fig. 17). You set the coagulation condition by adjusting the time and output power, but there is a wide range of settings ranging from strong irradiation that creates white burn on the retina to non-therapeutic irradiation (Fig. 18). The important factor for attaining minimally invasive laser is how you control energy within the therapeutic range. If it is 30-50% threshold, you can hope to achieve treatment without causing any permanent damaging effects. If it is 50-90%, you can hope to achieve coagulation levels that are repairable although some damage will be done to RPE and the outer layer (Fig. 19). If you simply half the time and half the power, the energy becomes 50%; however, this does not mean the actual level of tissue damage is half. By utilizing a special algorithm, PASCAL's Endpoint Management software flexibly controls the level of tissue damage.



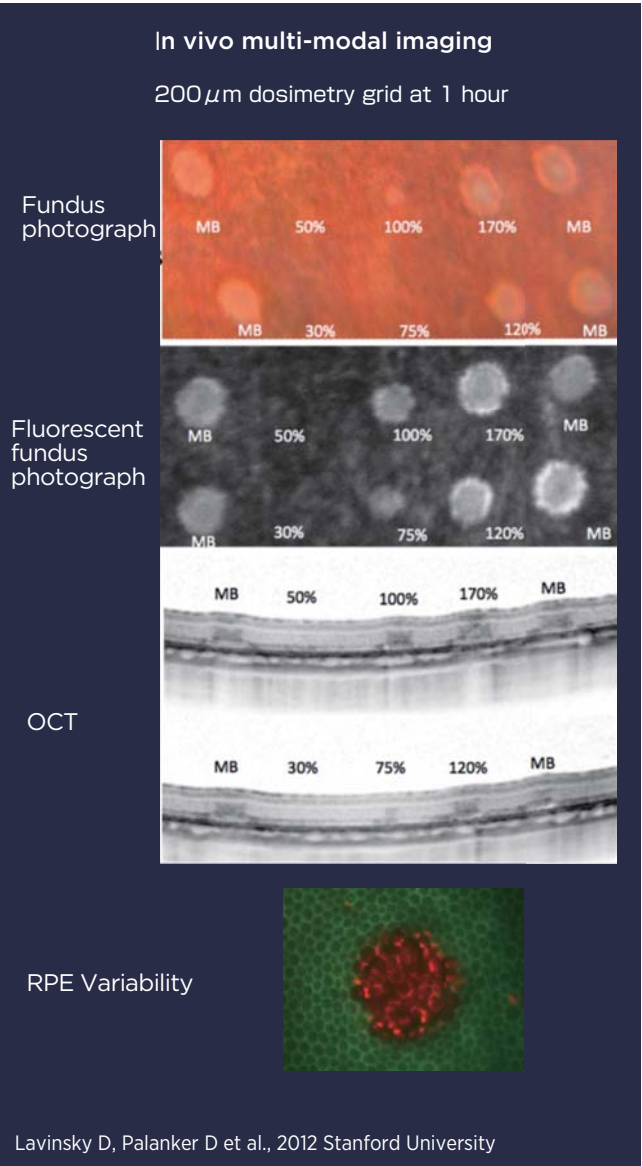
(Figure 14)



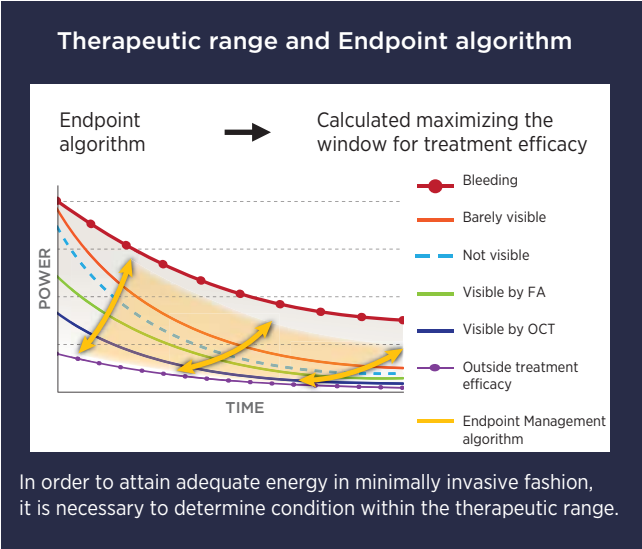
(Figure 15)



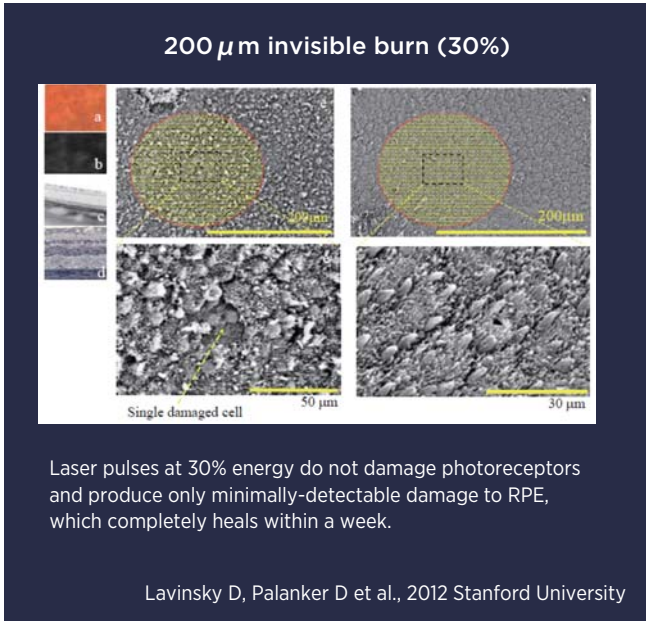
(Figure 16)



(Figure 17)



(Figure 18)

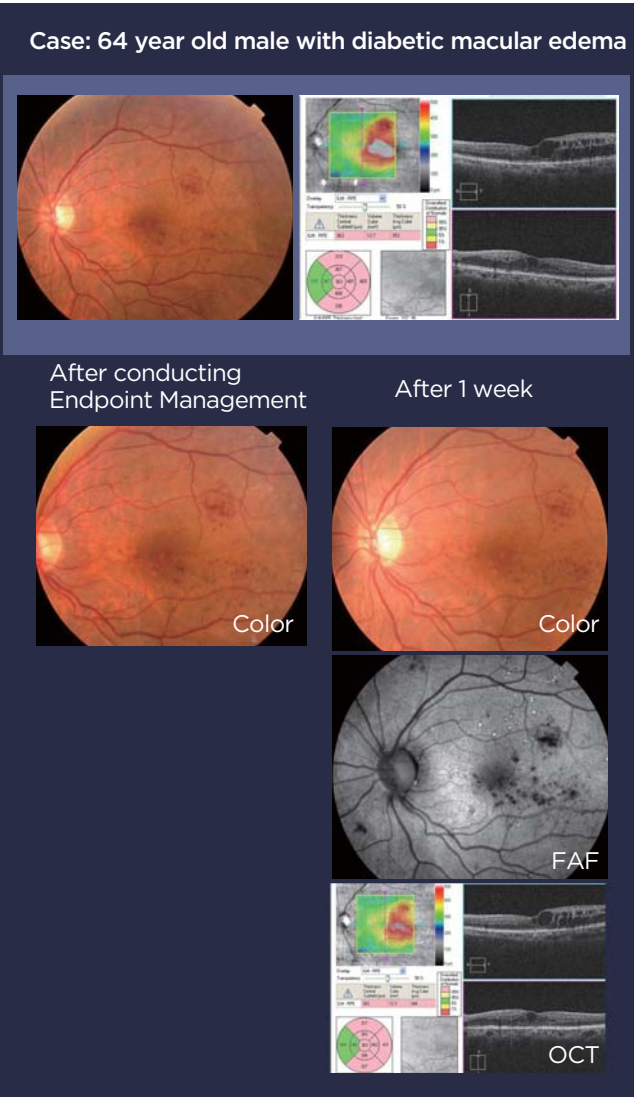


(Figure 19)

Future Direction of Non-invasive Laser Treatment Strategy

Diabetic macular edema (64 years old, male)

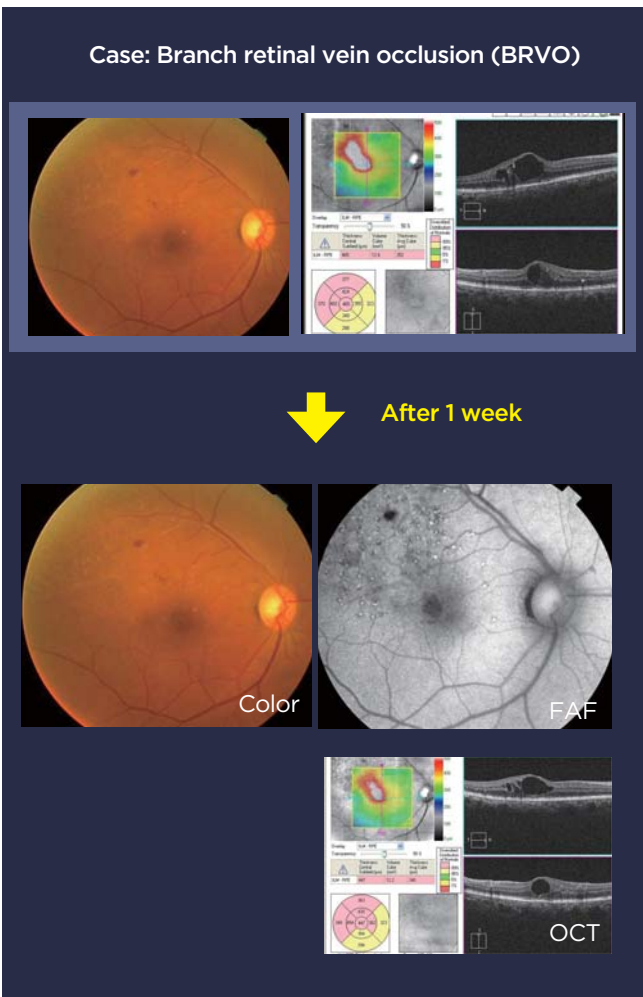
This is a patient with diabetic macular edema. In the image right after Endpoint Management was conducted, you can see the areas Titrated and the landmarks. Although you can confirm the Titration and landmark laser irradiation scars on the FAF image 1 week later, it is difficult to confirm where the coagulated areas are on the color fundus image. The edema is clearly subsiding in the OCT image (Fig. 20). Fig. 21 is a case of branch retinal vein occlusion (BRVO), you can confirm slight landmarks on the image after 1 week and the edema is slightly subsiding.



(Figure 20)

Summary

By utilizing Endpoint Management, the surgeon can freely control the energy until the point where coagulated areas may or may not be seen. For subthreshold coagulation, you cannot see the coagulated areas, but, by utilizing the landmark function, you can know which area has been irradiated. Because there are fixation targets, you can safely irradiate while having patients look at that fixation target. In addition, you can conduct grid pattern laser photocoagulation that is not susceptible to the surgeon's skill. Time is changing from traditional destructive lasers that coagulated tissues to treatment that stimulate tissues without destroying them. I believe the era for destructive lasers has ended and treatment will change from Photocoagulation to Photostimulation.



(Figure 21)



Overview of Endpoint Management ENDPOINT MANAGEMENT

New Approach for Laser Treatment

Decreases energy level to the percentage set compared to the baseline, and minimizes damage to cell tissue while maintaining treatment efficacy.

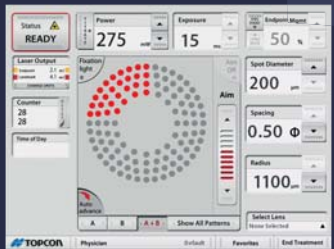
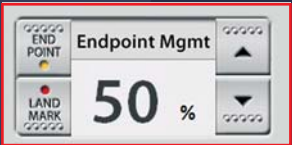
Relieves Patient Burden

By setting endpoints depending on the patient's needs, minimally invasive treatment can be provided. In addition, treatment can be done quickly and for the entire area because it is a pattern laser and thereby decrease patient burden.

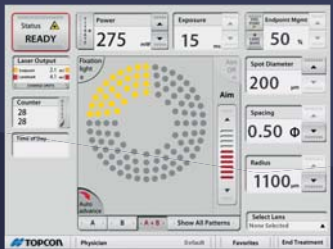
Easy Operation

The yellow dot on the pattern displayed in the control panel shows the area which will be irradiated using the energy level set by the Endpoint Management while the red dot shows the area which will be irradiated without decreasing the energy level due to the landmark function. It is also possible to turn OFF the Endpoint Management function of the PASCAL laser.

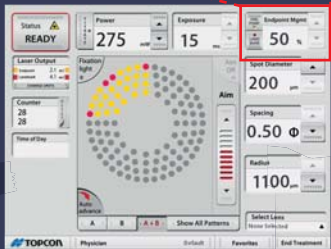
Displays the percentage set by the Endpoint function in an easy to understand way



Endpoint Management OFF



Endpoint Management ON /
Landmark OFF



Endpoint Management ON /
Landmark ON